Chest X-Rays

Adequacy of Film →

① Pt details → name, age, BOD

② FOV → Apices + Bx of lungs should be visible
Insp: Should be able to count 6 ant. ribs from apex → diaph.

③ Assess Rotation: Should have equal distance from medial borders of clavicles and spinous processes on both sides.
Interspinous - clavicular distance should be equal

④ Penetration: Should be able to see VC behind heart

⑤ Check side marker (L or R) to know orientation.

Radiographic Views

① PA - Post. → Ant. Good for well adults & older children.
heart should be < ½ of thoracic cavity

② AP - For pts in ICU.

③ Lateral - can help localise pathology

④ Supine - For pts in ICU on ventilators for breathing tube for babies

⑤ Pay attention: Heart size is larger on AP film compared to PA due to divergent X-Ray beams.

Assessing Film →

Heart → Heart size is assessed by cardiothoracic ratio. This is a ratio of the largest diameter of the heart to the largest diameter of the chest

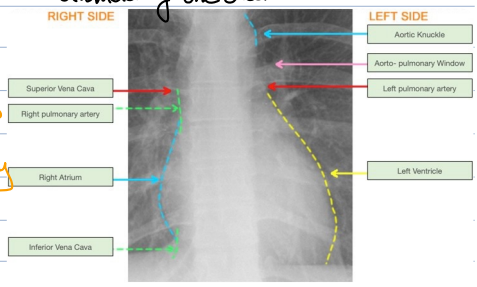

Lungs → Trachea lies R of midline & splits at carina @ T4. Right Main Bronchus is steeper than the left.
3RL, 2LL.

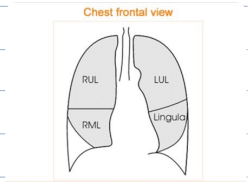

Parenchyma → Horizontal fissure, oblique fissure

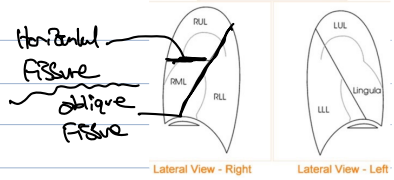

Pleura → Should be invisible. Will be visible if there is air or fluid. If a pneumothorax is present look for lack of pleural markings to the chest wall, a pleural line demarking the edge of the lung and one lung looking blacker than the other.
air in pleural space

Pneumothorax Present
↓
Is mediastinum central?

YES → Simple pneumothorax
Can compromise VR to the heart.

NO → Tension pneumothorax
↓
emergency: needs decompression w/ a cannula into the 2nd ICS.

Fluid in Pleura: To assess for pleural effusion, look for:
Space → ↑ density peripherally, mediastinal shift to contralateral side, blunting of costophrenic angle, and a meniscus.

Solid Pleural Thickening → Same as fluid but no meniscus or mediastinal shift.

Diaphragm → Dome border w/ chest wall = costophrenic recess. Border w/ heart = cardiophrenic recess. Pathology → ① Diaphragmatic hernia can go up into pleura. Can also make bowel loops.
② Morgagni hernia = bowels ant. to chest
Bochdalek hernia = bowels post. to chest.

Chest wall → ① Check breast shadows
② Nipple shadows
③ Hair artefacts
④ Bone lesions
⑤ Chest wall masses

Lung Hila → LPA passes over + behind left main bronchus. Sometimes lies above RPA. RPA lies infront of the bronchus but doesn't pass over it.
Hilar Point → Where UL pulm veins meet LL pulm arteries should be a V shape. Becomes distorted when LN are enlarged.
Hila Position → Very imp. L hilum should always be at the same lvl or higher than right b/c as the LPA hooks over the left main bronchus. The left hilum should NEVER be below the right (sign of LL volume loss).
• look at hila size + density is also imp.

Airways
Bones
Cardiac
Diaphragm - R dia should be higher than L
Expansion of lungs - 6th ant. rib should intersect mid point of diaphragm
Fields of lungs
Gadgets / attachments
Hila - Should be more prominent than rest of lung regions.

Pathology → Air is black. Everything else is white dep. on density.

↳ ① collapse
↳ ② consolidation
↳ ③ pleural effusion
↳ ④ pneumothorax
↳ ⑤ pulmonary edema